

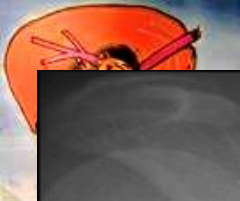
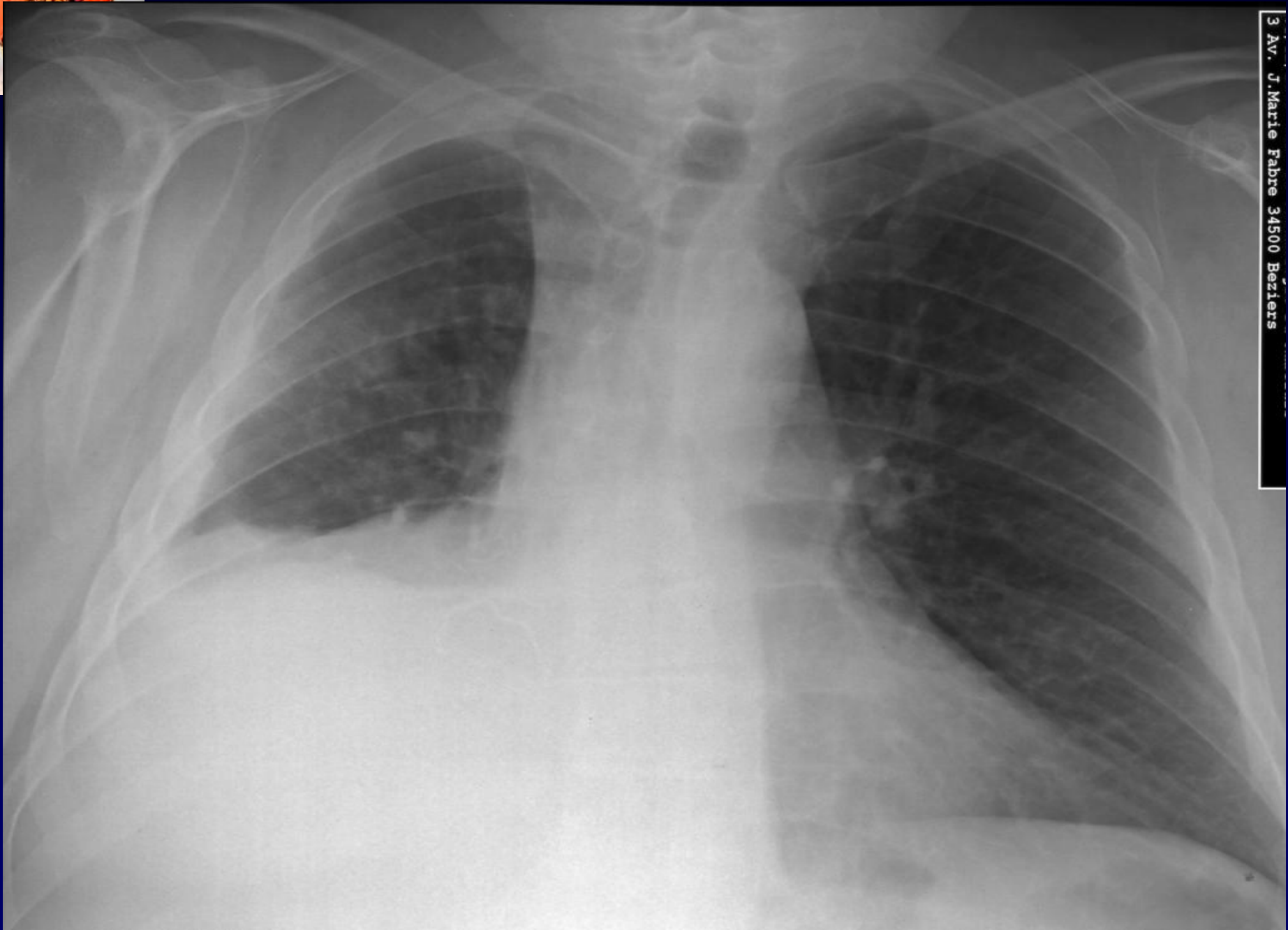


**G.DURAND J.GIRON P.FAJADET**

Homme de 56 ans

Néoplasie bronchique

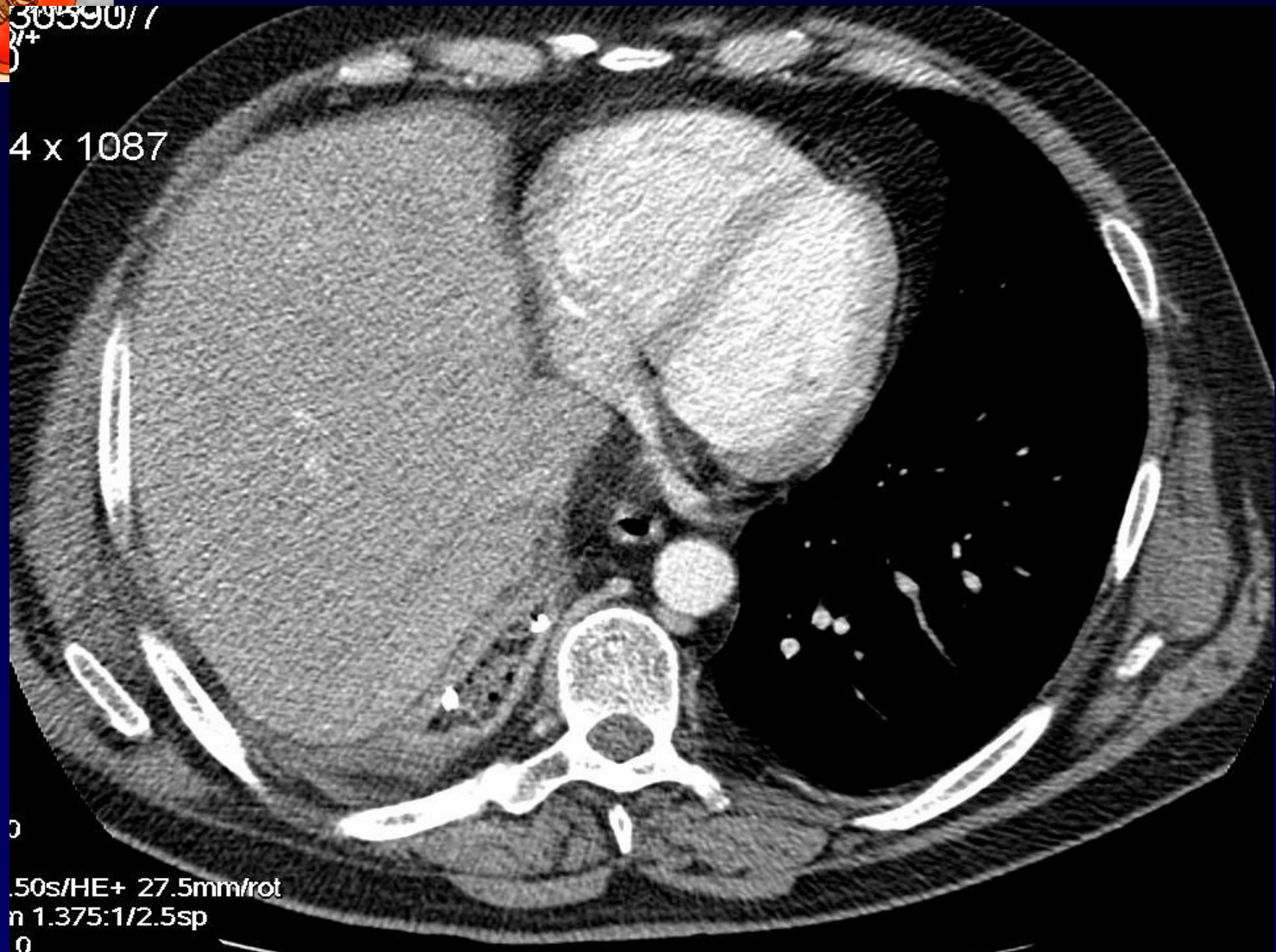
Lobectomie inf droite il y a 3mois, AEG, Fébricule



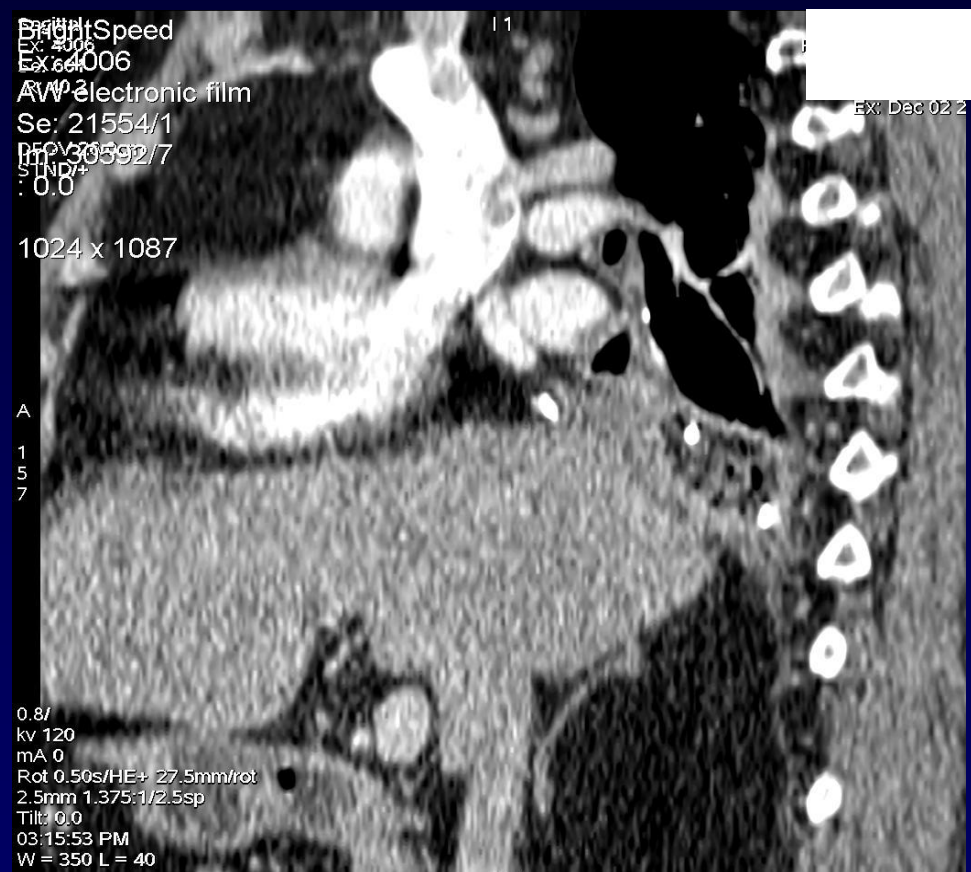
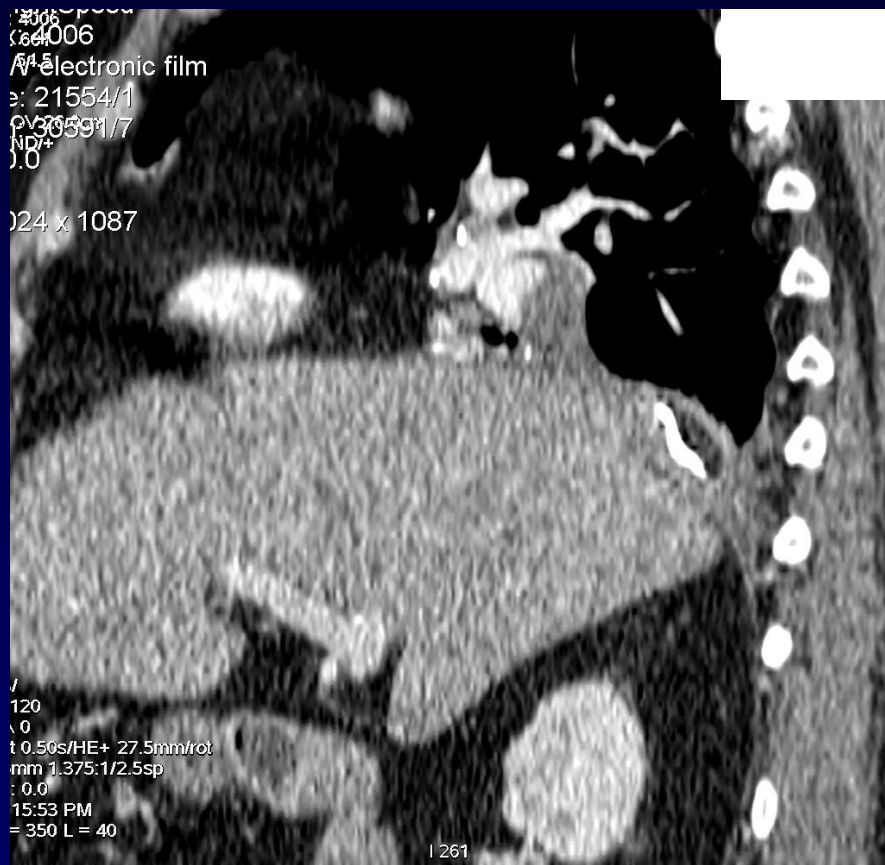
3059077  
2+

4 x 1087



0  
.50s/HE+ 27.5mm/rot  
n 1.375:1/2.5sp  
0





**Diagnostic ?**



WV electronic film  
e: 21554/1  
p: 30395/7  
ND+  
0.0

DoB: Feb 05 1  
Ex: Dec 02 2

024 x 1087

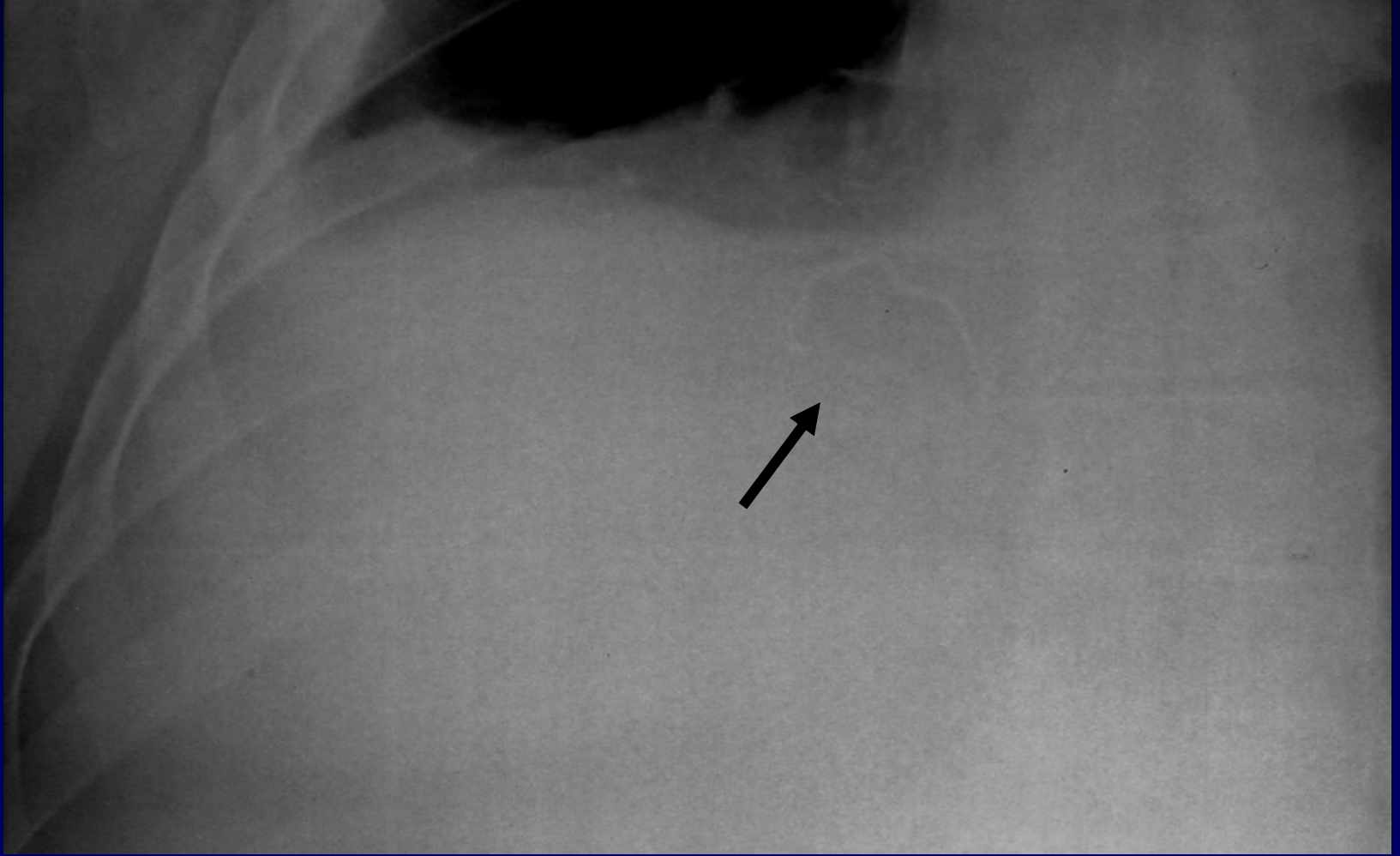
3/  
120  
A 0  
t 0.50s/HE+ 27.5mm/rot  
5mm 1.375:1/2.5sp  
t: 0.0  
:15:53 PM  
= 350 L = 40





**Diagnostic**

**Textilome post - chirurgie**





# Reprise chirurgicale